

Original article

The Italian MSUS Study Group recommendations for the format and content of the report and documentation in musculoskeletal ultrasonography in rheumatology

Annamaria Iagnocco¹, Francesco Porta², Giovanna Cuomo³, Andrea Delle Sedie⁴, Emilio Filippucci⁵, Walter Grassi⁵, Garifallia Sakellariou⁶, Oscar Epis⁷, Antonella Adinolfi⁸, Fulvia Ceccarelli¹, Orazio De Lucia⁹, Luca Di Geso^{5,10}, Valentina Di Sabatino⁸, Alessandra Gabba¹¹, Angelica Gattamelata¹, Marwin Gutierrez⁵, Laura Massaro¹, Marco Massarotti¹², Carlo Perricone¹, Valentina Picerno⁸, Viviana Ravagnani¹³, Lucrezia Riente⁴, Crescenzo Scioscia¹⁴, Esperanza Naredo¹⁵ and Georgios Filippou⁸, on behalf of the Musculoskeletal Ultrasound Study Group of the Italian Society of Rheumatology

Abstract

Objective. The objective of this study was to draw up a set of recommendations for the format and content of the musculoskeletal ultrasonography (MSUS) report in rheumatology.

Methods. A panel of rheumatologists, members of the MSUS Study Group of the Italian Society of Rheumatology, met in order to identify the main discrepancies in the MSUS report. A set of 15 recommendations was then defined, aimed at resolving the main discrepancies. They consisted of information about the motivations for the MSUS examination, the equipment, the US modalities and scanning technique, a list of the examined structures and findings, the scoring/grading systems, the number of images and main findings to include and conclusions. Subsequently a Delphi-based procedure was started in order to obtain agreement on a core set of recommendations. Consensus for each recommendation was considered achieved when the percentage of agreement was >75%.

Results. Three complete rounds were performed. The response rate was 85.2% for the first round, 78.3% for the second and 88.9% for the third. Finally, consensus was obtained for 14 of 15 statements. These 14 statements represent the recommendations of the group for the format and content of the report and documentation in MSUS in rheumatology.

Conclusion. To the best of our knowledge, our group has produced the first recommendations for the format and content of the report and documentation in MSUS in rheumatology. The report is an integral part of the MSUS examination and its use in a homogeneous form can help in the correct interpretation of the findings.

Key words: ultrasound, report, recommendations.

¹Rheumatology Unit, Università Sapienza, Rome, ²Rheumatology Unit, University of Florence, Florence, ³Rheumatology Unit, Second University of Naples, Naples, ⁴Rheumatology Unit, University of Pisa, Pisa, ⁵Rheumatology Unit, Università Politecnica delle Marche, Jesi (Ancona), ⁶Rheumatology Unit, IRCCS Policlinico San Matteo Foundation, Pavia, ⁷Rheumatology Unit, Niguarda Hospital, Milan, ⁸Rheumatology Unit, University of Siena, Siena, ⁹Rheumatology Unit, Istituto Ortopedico G. Pini, Milan, ¹⁰Rheumatology Unit, Ospedale Madonna del Soccorso, San Benedetto del Tronto (AP), ¹¹Rheumatology Unit, University of Cagliari, Cagliari, ¹²Rheumatology

Unit, Humanitas Clinical and Research Center, Rozzano, ¹³Rheumatology Unit, Azienda Ospedaliera Carlo Poma, Mantova, ¹⁴Rheumatology Unit, Università di Bari, Bari, Italy, and ¹⁵Rheumatology Unit, Hospital GU Gregorio Marañón, Madrid, Spain.

Submitted 4 May 2013; revised version accepted 9 September 2013.

Correspondence to: Annamaria Iagnocco, Rheumatology Unit, Dipartimento di Medicina Interna e Specialità Mediche, Sapienza Università di Roma, Viale Regina Elena 336, 00161 Rome, Italy. E-mail: annamaria.iagnocco@uniroma1.it

Introduction

Musculoskeletal (MS) ultrasonography (US) has progressively gained a central role in daily rheumatology clinical practice thanks to its intrinsic characteristics (non-invasiveness, absence of radiation hazards, wide availability, well accepted by patients, short examination time and multiregional assessment during the same scanning session) and to the flourishing scientific evidence of its relevant role in the diagnosis and assessment of rheumatic diseases as well as various MS disorders. However, despite the growing number of MSUS applications, to the best of our knowledge there are neither guidelines nor recommendations for the format and content of the US report, which represents an integral and crucial aspect of the MSUS examination.

This issue emerged from the first meeting of the recently founded MSUS Study Group of the Italian Society of Rheumatology, when the members discussed the current lack of consensus on the modalities for drawing up the MSUS report. The group agreed that this would negatively influence the reproducibility of MSUS findings between different ultrasonographers and would make the interpretation of findings by readers as well as US follow-up of rheumatic diseases difficult. Moreover, the current use of varied modalities of image documentation that accompany the US report was considered an additional aspect of crucial importance in the completion of the report and the need for obtaining unanimous points of view was underlined. All members of the group therefore decided to work on this problem. This project was developed with the aim of drawing up a set of recommendations for the format and content of the report and documentation in MSUS in rheumatology.

Methods

Study design

After the first meeting of a panel of rheumatologists, experts in MSUS and members of the MSUS Study Group of the Italian Society of Rheumatology, who discussed the main discrepancies in the format and content of the MSUS report, the work proceeded with a systematic search in the literature (PubMed, Embase and Cochrane Library database). Original articles focusing on the reporting modalities of MSUS in the field of rheumatic diseases were eligible for inclusion. Search strategies were developed for the main electronic databases (Table 1) and were limited to English-language articles published between January 1990 and June 2012, dealing with humans. Fig. 1 shows the selection process. Among the records that were identified through the search strategy, no study dealt with the reporting of MSUS in rheumatology.

On the basis of the previous discussions, an initial set of 15 statements was defined by some of the members of the steering committee of the study group (A.I., G.F., E.F., A.D.S., G.S., G.C., F.P.) and by an additional international expert (E.N.). Subsequently a Delphi-based procedure was started in order to obtain agreement on a core set

of recommendations to include in the report [1]. The set was submitted to all 27 members of the study group. Consensus for each recommendation was considered achieved when the percentage of agreement was >75%.

Questionnaire design and content

The questionnaire based on the issues discussed among the core group consisted of 15 questions that included the motivations for the execution of the MSUS examination, the equipment used, the US modalities and scanning technique, a list of the examined structures and the pathologic/normal findings, the scoring systems used and the grading of the lesions, the number of images and main findings to include in the documentation and the conclusions of the report. The participants were asked to answer each question, grading their agreement with each statement from 1 (strongly in disagreement) to 5 (strongly in agreement). In addition, they were invited to write their comments in the spaces included after the statements.

Analysis

The percentage of respondents who answered the questionnaire as well as the level of agreement of each statement were calculated. Group agreement with the issue under consideration was defined as >75% agreement.

Results

Three complete rounds were performed. The response rate was 85.2% (23/27) for the first round, 78.3% (18/23) for the second round and 88.9% (16/18) for the third round. Of the initial 15 statements, 1 obtained agreement after the first round (number 10), 9 after the second round (1, 2, 6–9, 11, 12, 14) and 4 after the third round (4, 5, 13, 15). No agreement was obtained for one recommendation (number 3). The first set of statements and the corresponding level of agreement obtained after the last round are reported in Table 2.

The final set of 14 recommendations is reported in Table 3. The main items to be reported in practice for MSUS are reported in Table 4. The issues addressed in the statements and the main points of discussion during the subsequent rounds are reported below:

Statement 1: Is it necessary to report the motivation for the exam?

Comments: The participants agreed that it is important to answer the clinical question, but unfortunately this is not always indicated or clear in the medical prescription. If the question is not clear, at least a generic indication (i.e. joint pain, joint swelling, etc.) should be indicated in order to link the findings to the patient's problem and to facilitate the reporting process.

Statement 2: Is it important to report the equipment used for the examination?

Comments: Modern US machines are equipped with high-frequency probes (up to 22 MHz or even higher) that allow a good spatial resolution and power Doppler performance. Many findings of chronic inflammatory joint

TABLE 1 Search strategy

PubMed	#1 'musculoskeletal' #2 ultrasonography (mesh) #3 ultrason* #4 sonograph* #5 'ultrasound' #6 #2 OR #3 OR #4 OR #5 #7 'report' #8 'documentation' #9 #7 OR #8 #10 #1 AND #6 AND #9
Embase	#1 musculoskeletal #2 ultrasonography #3 'ultrasonography'/de #4 #2 OR #3 #5 'ultrasound'/de #6 ultrasound #7 #5 OR #6 #8 'sonography'/de #9 sonography #10 #8 OR #9 #11 #4 OR #7 OR #10 #12 report #13 'documentation'/de #14 documentation #15 #13 OR #14 #16 rheumatic AND ('diseases' OR diseases) #17 #1 AND #11 AND #16
Cochrane	#1 musculoskeletal #2 ultrasound or ultrasonography or sonography: ti, ab, kw #3 report or documentation: ti, ab, kw #4 #1 and #2 and #3

Limits: humans, English language, publication data 1 January 1990–1 June 2012.

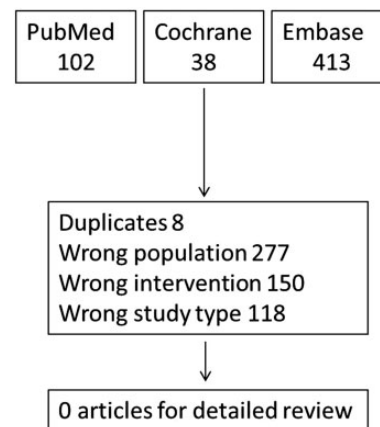
diseases, i.e. synovial tissue blood flow [2], are correlated with these parameters. Thus it is important for the reader to know the characteristics of the machine that was used.

Statement 3: Is it important to report all the US modalities used during the exam?

Comments: The participants in the study did not reach agreement regarding this statement. All of them agreed that the use of power Doppler should be clearly indicated even if is negative, but they believe that the use of other techniques [i.e. elastosonography, three-dimensional (3D) US, etc.] is still not widespread and thus their role in the diagnosis of joint diseases has not been fully demonstrated yet. Thus most of the participants believe that these techniques could be used but not necessarily reported if the results are not clear and do not add useful information.

Statement 4: Is it important to report all the structures examined, even if normal?

Comments: Participants believe that normal structures should be clearly listed in the final report only if they are directly linked with the motivation for the request for the

Fig. 1 Systematic search of the literature in the field: selection process.

US. If, for example, a general practitioner refers a patient for US with a suspicion of tenosynovitis of the flexor tendon of the third digit of the hand, in the report it should be clearly stated that there are no alterations of that tendon if it is normal. On the other hand, if there are other pathological findings in addition to the initial request, all of them should be reported. Participants also believe there is no need to list all the structures examined that are not correlated with the clinical question. A final statement that there are no further pathological findings could be sufficient and would improve the interpretation of the report.

Statement 5: Is it important to state the scanning technique used?

Comments: A circumstantial description of the scanning technique used during the exam should be used only if it adds relevant information for the reader. This could be the case in dynamic scanning for the assessment of some structures (i.e. impingement of the shoulder or ulnar nerve instability at the elbow). The main objection to this kind of approach is that it could be time consuming for the sonographer to report and may not be readily understood by the reader. On the other hand, it could be useful for the reader to understand the quality of the examination as well as for other sonographers when they are called upon to perform a follow-up examination.

Statement 6: Is it necessary to report pathological findings that are casually found and not linked with the reason for the examination?

Comments: All pathological findings of the examined area should be reported. However, the participants also believe that other pathological findings not related with the examination motivation should not occupy more space in the report than the main findings related to the motivation.

Statement 7: Is it important to grade the lesions found?

Comments: The group members obtained a high grade of agreement with this statement (95%). They believe that it is very important to grade the pathological findings,

TABLE 2 Set of statements and corresponding level of agreement obtained after three rounds (Delphi-based procedure)

Statement	Agreement, %
1. The motivation (e.g. clinical question to be addressed) for the US examination should be indicated at the beginning of the report. When the patient is referred to the US clinic by a general practitioner and the motivation is unclear, at least a generic indication based on a brief anamnesis should be indicated.	89
2. The equipment (i.e. US machines, type and frequency of the probe) used for the US examination should be indicated in the report, at least when such characteristics cannot be obtained from the images attached in the report. In any case, the reader should be able to obtain this information.	95
3. The reader should be able to understand the US modes used during the examination (not only power Doppler, but also other more recent techniques such as elastosonometry, 3D US, spectral analysis, contrast-enhanced US and others), as such modalities are still not universally used by all musculo-skeletal sonographers. These modalities could be clearly indicated at the beginning of the report or in the description. In any case, the reader should be able to obtain this information.	73
4. All the examined pathological structures should be listed in the report. Normal structures should be listed only when correlated with the motivation for the exam and preferably grouped and not isolated. For example, in case of a request for US of the hand for suspected flexor tendons tenosynovitis, a statement like 'no alterations of the flexor tendons of the hand' could be appropriate and less time consuming.	82
5. The details of the scanning technique (i.e. anatomic approaches, planes, static and/or dynamic) should be described in the report only if they add important information, e.g., alterations that are visible only in dynamic scans and not in static scans.	82
6. A description of the US pathological findings in the examined area should be provided independently of the motivation for the US examination. Normal findings not linked to the exam motivation can be omitted.	78
7. A semi-quantitative grading of the pathological findings (descriptive or numerical) can be provided, if applicable and described in the literature. This approach could be helpful for follow-up of the patients.	95
8. A quantitative measure of a lesion can be provided, accompanied by the normal values according to the literature, if validated and universally accepted (e.g. CSA values of the median nerve in CTS), and the clinical relevance of the measure, if applicable.	83
9. Anatomic structures that cannot be properly or entirely visualized (e.g. knee menisci) should not be reported as normal, but if the clinical image is suggestive of a lesion of such structure, the limits of the method should be clearly reported; on the other hand, if present, pathological findings should be reported.	100
10. A conclusion should be provided, either at the end of the report or after the description of the lesion, with the indication of the pathological condition, according to internationally accepted terminology (e.g. synovitis, tenosynovitis, tendinopathy, etc.).	91
11. In the conclusion, the need for other appropriate tests or examinations should be indicated, if appropriate.	89
12. Diagnosis of a specific disease (i.e. RA, PsA, etc.) must be avoided. In the case of diseases where US has demonstrated high specificity (i.e. chondrocalcinosis, urate deposition disease, OA, etc.), the presence of such disease could be indicated if the findings are strongly suggestive of such disease.	89
13. After the conclusions, comments on the relevance or interpretation of the US findings in the clinical context should be avoided.	82
14. The US examinations should be documented with a representative number of scans showing the principal pathological findings and normal findings only when linked to the motivation for the examination.	89
15. In all documented US images, only essential information such as the site (i.e. II MCP right) should be provided. Other information such as the scan (i.e. transverse, longitudinal) or the name of the bones visible is not necessary.	91

CSA: cross-sectional area.

especially when an inflammatory arthritis is diagnosed or suspected. The only issue raised by the sonographers is the problem related to interreader agreement for the scoring. A semi-quantitative assessment of inflammatory changes was considered much more important for the evaluation of disease activity and follow-up of the patients than the possible risks related to interrater discordance.

Statement 8: Is it important to report lesions with quantitative measures?

Comments: The group agreed that quantitative values should be provided for all conditions that permit an accurate measurement. In this statement the word lesion has been considered in its wide meaning as any abnormality, therefore all 'abnormal' conditions such as enlargement of

nerves or thickening of tendons are considered as lesions. Thus the sonographers believe that when normal values are provided in the scientific literature for a specific feature, these values should also be mentioned in the report [e.g. cross-sectional area (CSA) values of the median nerve at the wrist] if they permit distinguishing a pathologic condition from a normal one.

Statement 9: How should the sonographer report the structures that are not entirely visible in US?

Comments: This was the point that obtained the highest agreement (100%). The participants believe that any detectable alteration of such structures should be clearly reported. On the other hand, when there are no direct or indirect signs of lesions of such structures, the

TABLE 3 The Italian MSUS Study Group recommendations for the format and content of the MSUS report and documentation in rheumatology

Statement
1. The motivation (e.g. clinical question to be addressed) for the US examination should be indicated at the beginning of the report. When the patient is referred to the US clinic by a general practitioner and the motivation is unclear, at least a generic indication based on a brief anamnesis should be indicated.
2. The equipment (i.e. US machine, type and frequency of the probe) used for the US examination should be indicated in the report, at least when such characteristics cannot be obtained from the images included in the report. In any case, the reader should be able to obtain this information.
3. All the examined pathological structures should be listed in the report. Normal structures should be listed only when correlated with the motivation for the examination and preferably grouped and not isolated. For example, in the case of a request for US of the hand for suspected flexor tendons tenosynovitis, a statement like 'no alterations of the flexor tendons of the hand' may be appropriate and less time consuming.
4. The details of the scanning technique (i.e. anatomic approaches, planes, static and/or dynamic) should be described in the report only if they add important information, e.g. alterations that are visible only in dynamic scans and not in static scans.
5. A description of the US pathological findings in the examined area should be provided independently of the motivation for the US examination. Normal findings not linked to the exam motivation can be omitted.
6. A semi-quantitative grading of the pathological findings (descriptive or numeric) can be provided, if applicable and described in the literature. This approach could be helpful for follow-up of the patients.
7. A quantitative measure of a lesion can be provided, accompanied by the normal values according to the literature, if validated and universally accepted (e.g. CSA values of the median nerve in CTS), and the clinical relevance of the measure, if applicable.
8. Anatomic structures that cannot be properly or entirely visualized (e.g. knee menisci) should not be reported as normal, but if the clinical image is suggestive of a lesion of such structure, the limits of the method should be clearly reported; on the other hand, if present, pathological findings should be reported.
9. A conclusion should be provided, either at the end of the report or after the description of the lesion, with the indication of the pathological condition, according to internationally accepted terminology (e.g. synovitis, tenosynovitis, tendinopathy, etc.).
10. In the conclusion, the need for other appropriate tests or examinations should be indicated, if appropriate.
11. Diagnosis of a specific disease (i.e. RA, PsA, etc.) must be avoided. In the case of diseases where US has demonstrated high specificity (i.e. chondrocalcinosis, urate deposition disease, OA, etc.), the presence of such disease could be indicated if the findings are strongly suggestive of such disease.
12. After the conclusions, comments on the relevance or interpretation of the US findings in the clinical context should be avoided.
13. The US examinations should be documented with a representative number of scans showing the principal pathological findings and normal findings only when linked to the motivation for the examination.
14. In all documented US images, only essential information such as the site (i.e. II MCP right) should be provided. Other information such as the scan (i.e. transverse, longitudinal) or the name of the bones visible is not necessary.

CSA: cross-sectional area.

TABLE 4 Main items to be reported in practice for musculoskeletal US

1. Describe the equipment used.
2. Provide a description of all the pathological findings using scoring methods or appropriate measurements.
3. Provide a list of normal structures only if directly linked to the motivation for the examination.
4. Provide a final comment on the findings according to the motivation for the examination.
5. Indicate the need for other examinations if appropriate.
6. Indicated the diagnosis if appropriate.
7. Avoid comments on the relevance of the findings.
8. Attach an adequate number of images to the pathological findings described in the text.
9. Report only essential information on the images.

sonographer should avoid reporting them as normal. The clinical impression of the examiner is also very important in this regard. Sonographers believe that if the clinical picture is clearly indicative of lesions of those structures, the limits of the technique (e.g. lack of acoustic windows for a correct evaluation) should be reported.

Statement 10: Is a description of the lesions sufficient or should a conclusion with a diagnosis be provided?

Comments: The interpretation of the US findings should be the prerogative of the sonographer. The reader is not necessarily qualified to understand the clinical relevance of the findings and there is the risk of misinterpretation. Therefore, after a description of the US image, a conclusion should be provided. Conclusions could be integrated into the text after the description of each lesion or cumulatively at the end of the report after a global description. This statement reached consensus in the first round.

Statement 11: Should the sonographer indicate other tests or examinations?

Comments: The sonographer should indicate other examinations or tests if he/she believes that the US picture is not clear enough to respond to a specific question. This statement is also correlated with statement 9. If the sonographer, who is also a clinician, believes that another examination or test could provide more information on the pathologic condition, the sonographer should indicate it in the report.

Statement 12: Should the sonographer diagnose a disease on the basis of the US examination?

Comments: US findings may be suggestive of a disease, but only in rare cases are US findings included in the recommendations and diagnostic algorithms. This is the case, for example, for calcium pyrophosphate dehydrate crystal deposition disease [3]. In these conditions, where there is scientific evidence for the reliability of US in the diagnosis, the operator should indicate the specific condition in the report.

Statement 13: Should the sonographer try to interpret US data in the clinical context of the patient?

Comments: The sonographer should avoid interpretation of the US examination in the clinical context of the patient. The time dedicated to US examination does not always allow a complete medical history and clinical examination of the patient, and the lack of important elements could lead to a misinterpretation of the US findings. The final correlation of the US and clinical data should be the prerogative of the clinician who referred the patient.

Statement 14: How many images should be attached to the report?

Comments: The group agreed that all pathological findings should be documented with a sufficient number of images and that normal findings should be omitted. Normal structures should be documented only when directly linked with the motivation for the examination.

Statement 15: What information should be indicated in the images?

Comments: The participants agreed that a very detailed description of the structures illustrated in the photos would be time consuming and not relevant either for the sonographer (who does not need legends in order to understand the images) or for the reader (if he/she is not familiar with the US images he/she will not be able to interpret the findings). Only essential information should be reported, such as the side (right or left) and the structure in case of similarities (i.e. II or III MCP joint).

Discussion

After three Delphi rounds our group has produced the first recommendations for the format and content of the report and documentation of MSUS in rheumatology. This process derived from an agreement of >75% in the single items that was obtained for 14 statements. MSUS

for the assessment of joint pathology has been used increasingly in recent years, both by radiologists and non-radiologists [4]. In particular, MSUS has gained a relevant role in the assessment of different rheumatic diseases, and an increasing number of rheumatologists use MSUS as a routine and complementary examination to the clinical evaluation of patients. Particularly in Europe, but also in other continents (i.e. Americas and Asia), an increasing number of rheumatologists consider MSUS as a relevant imaging modality both for clinical and for research applications [5]. The diffusion of the use of MSUS has raised some issues related mainly to the training, competence and appropriateness of its applications and some of the main scientific societies have commissioned groups of experts in order to assess the usefulness of MSUS in diagnosing joint pathology [4, 5]. The experts of both radiology and rheumatology societies, after literature reviews, have drawn up a set of clinical indications for the use of MSUS [4, 5]. These recommendations could certainly be useful for ultrasonographers and may contribute to a further expansion and popularity of MSUS [5].

However, despite the growing evidence regarding the use of MSUS in rheumatology, to the best of our knowledge there are no guidelines or recommendations for the format and content of the MSUS report, which represents a fundamental and integral aspect of the MSUS examination.

General recommendations on the correct reporting of imaging examinations have been previously published by radiologists and it has been concluded that a 'good' report of medical imaging should be described by the eight Cs: clarity, correctness, confidence, concision, completeness, consistency, communication and consultation [6]. In addition, two features that are attributes to a 'good' radiology report are timeliness and standardization.

However, while the eight Cs may be somehow achievable, standardization of the MSUS report is a real challenge. This issue emerged immediately at the first meeting of the MSUS Study Group of the Italian Society of Rheumatology. All members agreed that incomplete and non-standardized reporting of US findings could negatively influence the clinical management and follow-up of patients with rheumatic diseases. On that occasion, several diversities were identified among the ultrasonographers and it was agreed that developing a study on the standardization of the MSUS report was a real need.

In other sectors of US imaging, studies on the efficacy of the report and attempts at standardization have been carried out. In a recent study [7] the authors tried to assess the adequacy of reporting US findings of the renal tract in children in a radiology department. The authors created a scoring system that includes five categories based on anatomical sites (kidney general documentation, kidney specific comments, distal ureter, urinary bladder and anteroposterior renal pelvis width), with each of these divided into subitems. The maximum score in a complete report is 21. The most frequent report-adequacy score was 6 of 21 (range 3–12). The authors concluded that the reporting of paediatric renal tract

US was poorly standardized but also independent of performing/reporting doctor, type of study and indication. They also proposed a template for the correct compilation of the report.

A similar approach has been used in the field of echocardiography. Homorodean *et al.* [8] created a template for the reporting of echocardiography with a pyramid-like structure. The template was proven to fulfil the requirements for completeness and flexibility of the reporting methodology. The next step in the implementation process was to test the reporting methodology during echocardiographic examination (real-time conditions), proving its feasibility in daily clinical practice.

However, the MSUS report is difficult to standardize and the creation of a template is almost impossible since there are numerous structures to be examined and analysed in every anatomic area and a generic template will not always be suitable. An example is the hand: a complex anatomic area composed of 14 joints and a large number of ligaments, entheses, cartilage, fat pads and other structures. In addition, a large number of tendons (including flexors, extensors, adductors and abductors) and muscles are present. Moreover, the skin, subcutaneous tissues, palmar aponeurosis, nerves and nails are additional structures to analyse, given that each of them is a possible site of involvement in rheumatic diseases.

Recently Hobson-Webb *et al.* [9] described the reporting of the results of diagnostic neuromuscular US (NMUS). NMUS is becoming an important extension of the electrodiagnostic examination and a widely accepted means of enhancing diagnostic capabilities in the EMG laboratory, particularly in patients with entrapment mononeuropathies. The recommendations proposed by the experts were strongly influenced by the EMG report. The authors recommended reporting the demographic data of the patient (age, ethnicity, height, weight and gender) and optionally other comorbidities that could be related to neurological pathology. Interestingly, those recommendations are aligned with ours both in terms of technical features of the equipment and measurements to describe anatomic structures (i.e. values of the CSA of the nerves).

The present article has some limitations, which are mostly related to the intrinsic issue that we analysed. First, there is no scientific literature in the reporting of MSUS. For this reason, the experts had to propose recommendations based on their own experience and not on scientific evidence. For the same reason, it has not been possible to calculate the strength of the propositions.

It is clear to us that MSUS reporting is a very challenging issue. This project was meant to provide general recommendations on the contents of the MSUS report, which should contain certain information that is useful in describing the various pathologic findings and provide information to the clinician. We believe that the adoption of a shared form of reporting US findings could be a relevant step towards MSUS standardization. Further testing of our recommendations in daily clinical and US practice could

help us to understand their real applicability and usefulness in MSUS reporting in rheumatology.

Conclusions

To the best of our knowledge, our group has produced the first recommendations for the format and content of the MSUS report and documentation in rheumatology (Table 3). The report is an integral part of the MSUS examination and its use in a homogeneous form can help in the correct interpretation of the findings.

Rheumatology key messages

- The musculoskeletal US report is an integral part of the sonographic examination.
- Using the musculoskeletal US report in a homogeneous style can assist in the correct interpretation of US findings.

Acknowledgements

The authors acknowledge Wendy Doherty for the English revision of the manuscript.

Disclosure statement: The authors have declared no conflicts of interest.

References

- 1 Jones J, Hunter D. Consensus methods for medical and health services research. *BMJ* 1995;311:376–80.
- 2 Torp-Pedersen ST, Terslev L. Settings and artefacts relevant in colour/power Doppler ultrasound in rheumatology. *Ann Rheum Dis* 2008;67:143–9.
- 3 Zhang W, Doherty M, Bardin T *et al.* European League Against Rheumatism recommendations for calcium pyrophosphate deposition. Part I: terminology and diagnosis. *Ann Rheum Dis* 2011;70:563–70.
- 4 Klauser AS, Tagliafico A, Allen GM *et al.* Clinical indications for musculoskeletal ultrasound: a Delphi-based consensus paper of the European Society of Musculoskeletal Radiology. *Eur Radiol* 2012;22:1140–8.
- 5 McAlindon T, Kissin E, Nazarian L *et al.* American College of Rheumatology report on reasonable use of musculoskeletal ultrasonography in rheumatology clinical practice. *Arthritis Care Res* 2012;64:1625–40.
- 6 Reiner BI. The challenges, opportunities, and imperative of structured reporting in medical imaging. *J Digit Imaging* 2009;22:562–8.
- 7 Govender N, Andronikou S, Goodier MDM. Adequacy of paediatric renal tract ultrasound requests and reports in a general radiology department. *Pediatr Radiol* 2012;42:188–95.
- 8 Homorodean C, Olinic M, Olinic D. Development of a methodology for structured reporting of information in echocardiography. *Med Ultrason* 2012;14:29–33.
- 9 Hobson-Webb LD, Boon AJ. Reporting of the results of diagnostic neuromuscular ultrasound: an educational report. *Muscle Nerve* 2013;47:608–10.